Histopathology

Histopathology 2026 DOI: 10.1111/his.70088

REVIEW

Mucin-producing breast lesions: a practical approach to diagnosis

Sunayana Misra,[1,2] Mihir Gudi,[2] Kimberly H Allison,[3] Edi Brogi,[4] Cecily Quinn,[5] Hannah Y Wen[4] & Puay Hoon Tan[2,6,7,8]

[1]*Department of Pathology, Sir Ganga Ram Hospital, New Delhi, India,* [2]*Department of Pathology and Laboratory Medicine, KK Women's and Children's Hospital, Singapore,* [3]*Department of Pathology, Stanford University School of Medicine, Stanford, California,* [4]*Department of Pathology and Laboratory Medicine, Memorial Sloan Kettering Cancer Center, New York, New York, USA,* [5]*Irish National Breast Screening Programme and Department of Histopathology, St Vincent's University Hospital, and School of Medicine, University College, Dublin, Ireland,* [6]*Luma Medical Centre, Singapore,* [7]*Department of Anatomy, Yong Loo Lin School of Medicine, National University of Singapore, Singapore and* [8]*Department of Pathology, University of Western Sydney, Sydney, Australia*

Misra S, Gudi M, Allison K H, Brogi E, Quinn C, Wen H Y & Tan P H (2025) *Histopathology*. https://doi.org/10.1111/his.70088

Mucin-producing breast lesions: a practical approach to diagnosis

Mucin-producing breast lesions encompass a diverse range of entities with varied morphologies, distinct molecular genetics and different outcomes. Mucocele-like lesions (MLLs) are being increasingly recognised and sampled due to advancements in imaging techniques. These lesions can present with or without epithelial proliferation and atypia, which hold prognostic significance. Diagnosing MLLs on limited core needle biopsy (CNB) samples can be challenging. Mucinous breast carcinoma (MuBC) generally has an excellent prognosis in its pure form. Recent studies indicate that mucin-producing invasive cancers with micropapillary growth pattern, high nuclear grade or HER2 overexpression/amplification may not fare as well as their pure counterparts, suggesting that they should be distinguished from pure MuBCs. Invasive lobular carcinoma with extracellular mucin (ILCEM) is an emerging subtype of ILC characterised by neoplastic cells in cords, nests and trabeculae, often with signet ring morphology, floating in extracellular mucin. This can lead to misdiagnosis as a ductal phenotype due to varied architectural patterns or a MuBC due to the presence of extracellular mucin. This review highlights the spectrum of mucin-producing breast lesions, focusing on the above-mentioned entities along with recent molecular updates, potential mimics and diagnostic pitfalls on CNB specimens. Awareness of these entities, a practical approach to their diagnosis, combined with judicious use of immunohistochemistry, are crucial for accurate diagnosis by pathologists, which is in turn essential for guiding clinical decision making for optimal patient outcomes.

Address for correspondence: Puay Hoon Tan, Luma Medical Centre, Paragon, 290 Orchard Road, Lobby C #09-30/31, Singapore 238859, Singapore. e-mail: tanpuayhoon28@gmail.com

Abbreviations: ADH, atypical ductal hyperplasia; AUC, area under curve; CCC, columnar cell change; CCH, columnar cell hyperplasia; CK, cytokeratin; CNB, core needle biopsy; DCIS, ductal carcinoma in situ; ER, oestrogen receptor; FEA, flat epithelial atypia; FISH, fluorescent in situ hybridisation; H&E, haematoxylin and eosin; HER2, human epidermal growth factor receptor 2; HR, hormone receptor; IHC, immunohistochemistry; ILC, invasive lobular carcinoma; ILCEM, invasive lobular carcinoma with extracellular mucin; IMPC, invasive micropapillary carcinoma; LCIS, lobular carcinoma in situ; MCA, mucinous cystadenocarcinoma; MEC, mucoepidermoid carcinoma; MLL, mucocele-like lesions; MPMC, micropapillary pattern of MuBC of the breast; MuBC, mucinous breast carcinoma; NCCN, National Comprehensive Cancer Network; NET, neuroendocrine tumours; OS, overall survival; PMuBC, pure MuBC; PR, progesterone receptor; ROC, receiver operating characteristic; SEER, surveillance, epidemiology and end results; SPC, solid papillary carcinoma; TILs, tumour infiltrating lymphocytes; UDH, usual ductal hyperplasia.

© 2026 John Wiley & Sons Ltd.

Keywords: breast, invasive lobular carcinoma with extracellular mucin, micropapillary mucinous breast carcinoma, mucinous breast carcinoma, mucocele-like lesion

Introduction

Glycoconjugates, which include mucins, proteoglycans and various glycoproteins, are complex carbohydrates covalently linked to proteins or lipids.[1] Mucins consist of polysaccharide chains covalently linked to a protein core consisting of tandemly repeated serine or threonine-rich amino acid sequences via *O*-glycosidic linkages.[2] Depending on the charge of their polysaccharide components, mucins can be classified into three categories: neutral mucins which contain uncharged monosaccharides; weakly acidic or sialomucins which possess carboxylate groups; and strongly acidic or sulfomucins, which are distinguished by their sulphate groups.[1]

Mucins are further categorised into secreted and membrane-bound forms based on their structure and localisation.[3] Secreted mucins are released from the apical membranes of epithelial cells, serving as a protective barrier against harmful substances and pathogens while also lining the ductal surfaces of organs such as the liver, breast, pancreas and kidney.[3] In contrast, membrane-bound mucins remain anchored in the plasma membrane due to a hydrophobic transmembrane domain and are involved in various signalling pathways that regulate cellular functions.[4,5]

In breast cancer, differential expression of these mucins has been observed. The overexpression of membrane-bound mucins such as MUC1 is linked to oncogenesis through mechanisms that promote receptor tyrosine kinase signalling, constitutively activating survival pathways, facilitating immune evasion and downregulating stress-induced cell death pathways.[6,7] MUC2, a gel-forming secreted mucin, shows significantly higher expression in mucinous carcinoma of the breast (MuBC) compared to invasive breast carcinoma of no special type (IBC-NST), contributing to its less aggressive nature by forming a mucous gel barrier that restricts tumour spread.[8,9] Additionally, intracellular mucin can be found as droplets within tumour cells in neoplastic non-mucinous breast lesions, including lobular carcinoma in situ (LCIS), ductal carcinoma in situ (DCIS) and invasive lobular carcinoma (ILC). Mucinous metaplasia of benign breast epithelium has also been sparingly reported.[9]

Proteoglycans, often referred to as "connective tissue mucins" or "mesenchymal mucins," are large glycoconjugate complexes formed by highly acidic glycosaminoglycans attached to a protein core.[1,10] Unlike mucins produced by epithelial cells, proteoglycans are secreted by connective tissue cells.[10] Notably, many non-mucin secreting breast tumours can induce significant mucoid (epithelial tumours) or myxoid (mesenchymal tumours) stromal alterations resembling extracellular mucin secretion.

In this review, we discuss the spectrum of mucin secreting epithelial breast lesions (summarised in Table 1) including the latest molecular updates, potential mimics and diagnostic pitfalls on core needle biopsy (CNB) specimens.

Mucocele like lesion

Mucocele-like lesion (MLL) of the breast was first described by Rosen in 1986 as a benign lesion composed of mucin-containing cysts lined by flat or low cuboidal epithelium with or without extravasated mucin, akin to the mucocele of minor salivary glands.[11] The pathophysiology of MLL is attributed to excessive production of mucinous secretions, leading to cystic distention of glands and eventual rupture causing pools of mucin to dissect through the breast stroma. Fadare *et al.* described a breast lesion that exhibited a morphologic continuum between MLL and columnar cell hyperplasia (CCH), both of which had a remarkably low proliferation index.[12] These components co-existed within the same duct spaces, suggesting that MLL and CCH without atypia may simply represent lesions that share derangements in the unfolding of the terminal-ductular lobular units.[12] MLL has been previously categorised into classic and variant types with classic MLL being characterised by a discrete group of cystic structures and variant MLL having a more diffuse distribution, further categorised as duct ectasia-like or cystic mastopathy-like.[13]

MLL of the breast is rare, identified in <1% of core biopsies and presenting at a mean age of 54 years (range, 27–82 years) which is younger than MuBC.[14] MLL may be detected as a palpable breast mass, a mammographic abnormality, or an incidental finding.

© 2026 John Wiley & Sons Ltd., *Histopathology*

13652559, 0, Downloaded from https://onlinelibrary.wiley.com/doi/10.1111/his.70088 by George Mason University, Wiley Online Library on [10/03/2026]. See the Terms and Conditions (https://onlinelibrary.wiley.com/terms-and-conditions) on Wiley Online Library for rules of use; OA articles are governed by the applicable Creative Commons License

Table 1. Clinico-pathologic features of mucinous breast lesions

Lesion	Clinical features	Radiology	Gross features	Histopathology	Immunohistochemistry	Prognosis
Mucocele-like lesion (MLL)	Rare, mean age 54 years Maybe associated with atypia/DCIS	Cystic lesion with mucinous content; prominent calcifications, may mimic type A pure MuBC	Dilated ducts filled with mucin; may rupture and release mucin into stroma	Cystic ducts lined by bland cuboidal epithelium, acellular mucin in stroma. No significant atypia if benign	MLL without atypia: No specific markers MLL with atypia (ADH/DCIS): ER- strong diffuse, CK5, CK14- negative and p63- peripheral (+/−)	Excellent if benign. Upgrade to carcinoma may be seen if associated with atypia and DCIS
Mucinous breast carcinoma (MuBC)	Common in older women; slow-growing mass; often hormone receptor-positive	Hypoechoic mass on ultrasound; well-circumscribed on mammography	Gelatinous soft to viscous mass with abundant extracellular mucin	Tumour cells floating in pools of extracellular mucin; pure type (>90% mucin) and mixed type (<90% mucin)	ER/PR-positive, HER2-negative; low Ki-67 index in pure type	Pure type has excellent prognosis; mixed type has slightly worse outcomes and higher nodal metastasis
Mucin-producing carcinoma with high nuclear grade and/or HER2 positivity: IBC-NST with mucin production	Younger mean age than classic MuBC, can be hormone receptor negative and HER2 positive	Hypoechoic mass on ultrasound; well to partly circumscribed on mammography	Similar to MuBC, but often higher clinical stage, lymph node involvement	Mucin-producing BC with high nuclear grade, can have areas of necrosis, associated high-grade DCIS, higher frequency of signet-ring cells, micropapillary pattern	ER/PR positive or negative HER2 positive Higher Ki67 labelling index (>15%)	Worse prognosis than pure MuBC due to higher likelihood of lymph node metastasis
Mucinous micropapillary carcinoma (MPMC)	Variably defined, but reported series suggest a younger age and higher stage at presentation	Irregular mass with more frequent lymph node involvement	Ill-circumscribed gelatinous mass lesion	Variable definitions and overlapping features with classic pure mucinous carcinoma (both can have an inverted growth pattern) make it unclear if this is a distinct subtype. When micropapillary growth is particularly prominent in an otherwise typical MuBC, especially if associated with LVI, it can be mentioned as a potentially high risk feature	ER/PR positive, may show HER2 overexpression/amplification (similar to invasive micropapillary carcinoma) – if HER2 positive, recommend classifying as invasive micropapillary carcinoma or IBC-NST with mucin production. MUC1/EMA staining is not recommended since an inverted pattern can also be seen in classic pure MuBC	Unclear if associated with a worse prognosis than pure MuBC when high-grade and HER2 positive cases are excluded
Solid papillary carcinoma (SPC)	Older women; often presents as a palpable retro-aerolar mass with nipple discharge	Solid mass with circumscribed margins on imaging; may mimic benign lesions	Well-defined solid to multinodular mass with fleshy to gelatinous cut surface. May contain mucin-filled spaces	Tumour cells arranged in variable circumscribed nodules with delicate fibrovascular cores; neuroendocrine differentiation is common	ER/PR positive, HER2 negative Neuroendocrine markers often positive (synaptophysin, chromogranin)	Indolent behaviour but potential for local recurrence if incompletely excised
Invasive lobular carcinoma with extracellular mucin (ILCEM)	Usually presents as a large mass in postmenopausal women	Irregular hypoechoic lesion on ultrasound; ill-defined margins on mammography	Diffuse, infiltrative pattern, may be without distinct mass formation	Small dyscohesive tumour cells within pools of extracellular mucin; loss of E-cadherin expression typical of ILCs	ER/PR positive, HER2 negative in most cases; E-cadherin loss due to *CDH1* mutation is common	Prognosis depends on stage but similar to other ILC subtypes if detected early
Mucinous cystadenocarcinoma (MCA)	Extremely rare; presents as a palpable mass, often in postmenopausal women	Complex cystic lesion with solid component	Solid-cystic nodules with papillary excrescences and mucus filled cavities	Tall columnar tumour cells forming papillary structures; abundant intra- and extracellular mucin	Typically triple-negative (ER, PR, HER2: negative); expresses MUC1, MUC6; MMR proficient	May be aggressive but rare lymph node metastasis if detected early. Need to exclude metastasis
Mucoepidermoid carcinoma (MEC)	Very rare breast cancer subtype resembling salivary gland tumour analogue	Complex solid-cystic lesion on imaging with calcifications	Solid and cystic nodules with mucus-filled spaces	Mixture of squamous, glandular and intermediate cells suspended in extracellular mucin; high-grade tumours show pleomorphism and necrosis	Triple-negative phenotype common (ER, PR, HER2-negative); may express p63 and CK5/6 indicating squamous differentiation	High-grade MEC- Poor prognosis due to aggressive nature and high metastatic potential

DCIS, ductal carcinoma in situ; EMA, epithelial membrane antigen; ER, oestrogen receptor; HER2, human epidermal growth factor receptor 2; IHC, immunohistochemistry; LVI, lymphovascular invasion; MMR, mismatch repair; MUC, mucin; PR, progesterone receptor.

© 2026 John Wiley & Sons Ltd., *Histopathology*

13652559, 0, Downloaded from https://onlinelibrary.wiley.com/doi/10.1111/his.70088 by George Mason University, Wiley Online Library on [10/03/2026]. See the Terms and Conditions (https://onlinelibrary.wiley.com/terms-and-conditions) on Wiley Online Library for rules of use; OA articles are governed by the applicable Creative Commons License

The most common presentation is indeterminate microcalcifications, identified in up to 74% of cases on mammography.[15] The microcalcifications are typically clustered and pleomorphic, but may also be coarse, fine or granular. When MLL presents as a mass, it is typically described as round or lobulated, with or without well-defined margins and may appear as multiple lesions, sometimes forming a rosary bead-like configuration.[16] MLL is a descriptive terminology as it may be associated with a spectrum of neoplastic epithelial lesions including atypical ductal hyperplasia (ADH), DCIS and invasive carcinoma, with the key diagnostic feature being the nature of the epithelium lining the mucin-filled cysts and/or associated with the extracellular mucin.[17]

PATHOLOGY

For lesions that are macroscopically visible, MLL appears as a well or poorly defined multiloculated cystic nodule having a mucoid cut surface with grey-yellow flecks and gritty texture.[17,18] Most MLLs measure <2 cm, although the size range is wide (0.1–10 cm).[19] MLL is characterised by cysts with abundant mucin and at least focal rupture causing mucin extravasation into the stroma (Figure 1A,B).[18] The mucin is neutral or weakly acidic and shows a pale-blue grey, variable basophilic staining on the haematoxylin and eosin (H&E) stain occupying the entire duct without any fracture lines or scalloped contours.[18] Associated coarse, chunky calcifications are frequent while stromal fibrosis and chronic inflammation may also be seen. A MLL associated with benign ducts, lobules, columnar cell change (CCC) and benign proliferative changes is categorised as MLL without atypia, while that with flat epithelial atypia (FEA) and ADH has been classified as MLL with atypia.[17,18,20] It is recommended, however, that the nature of epithelial atypia is specifically categorised for clarity and management.

The molecular genetics of MLLs are not well understood, with limited insights derived from MLL with associated MuBC. Key knowledge gaps include the role of MUC2, PIK3CA mutations in atypical MLLs and genetic factors leading to invasive carcinoma. Future studies incorporating clinical and molecular data are needed to provide greater clarity.[15,20]

DIFFERENTIAL DIAGNOSIS

On CNB specimens, cyst rupture or attenuation of the lining epithelium of MLL can make it difficult to properly evaluate the cytological features. Cystic hypersecretory lesions, characterised by dilated cysts with prominent intraluminal secretions, may resemble MLL; however, the cyst lining is usually columnar with apical blebs, and the secretions are colloid-like, dense and eosinophilic, with fractured lines and scalloped contours.[21] Fibrocystic changes with mucin-filled cysts may resemble MLL on low magnification; however, they do not show rupture with extravasated mucin. Breast lesions with stromal mucin, such as nodular mucinosis, myxoma and myxoid fibroepithelial lesions, post-therapy myxoid stromal degeneration and biopsy site gels are other entities that may resemble the extravasated mucin of an MLL, especially in limited CNB samples, which will be discussed in the subsequent section.[17,18,22]

In MLL with ADH/ DCIS, the architectural and cytologic criteria for atypia adhere to the definitions for these entities (Figure 1C–F).[22] Briefly, ADH is characterised by partial involvement of ductal spaces by a uniform population of evenly spaced, relatively monomorphous cells with cribriform, micropapillary, or solid patterns involving less than two complete duct spaces or measuring not more than 2 mm while similar features when observed over a larger focus would define low-grade DCIS.[23] The most important and challenging differential diagnosis of MLL, on scant biopsy material, is MuBC. MLL and MuBC are thought to be two extremes of the same spectrum of lesions with the intermediate categories of MLL with ADH and DCIS.[17] Dislodgement of the epithelial lining of the MLL into the extravasated mucin may mimic paucicellular, focal MuBC. MLL lacks cytoarchitectural atypia unless there is an associated ADH or DCIS. In contrast, MuBC tends to exhibit higher cellularity, forming 3-dimensional clusters of neoplastic cells with variable nuclear atypia. Key distinguishing features favouring a benign MLL with detached cells include lack of cellularity and bland, nonatypical cytomorphology of associated epithelium, and often a retained myoepithelial cell layer can be demonstrated in support of detachment. In addition, MLL in the background, without any associated ADH or DCIS, may also support detachment rather than invasion. A history of prior biopsy in an area of detached epithelium (with associated stromal changes in the form of fibrosis, inflammation, fibrin and haemosiderophages) helps to assuage histological concern of potential invasion.[17,18,22] Presence of lesional changes such as DCIS should alert the pathologist to exclude an invasive carcinoma. Schnitt *et al.* reported that mucin neovascularisation is more common in MuBC than in MLLs (69.2% vs. 14.1%; $P = 0.0001$) which was further evident using CD31 IHC (97.6% vs. 13.8%,

© 2026 John Wiley & Sons Ltd., *Histopathology*

13652559, 0, Downloaded from https://onlinelibrary.wiley.com/doi/10.1111/his.70088 by George Mason University, Wiley Online Library on [10/03/2026]. See the Terms and Conditions (https://onlinelibrary.wiley.com/terms-and-conditions) on Wiley Online Library for rules of use; OA articles are governed by the applicable Creative Commons License

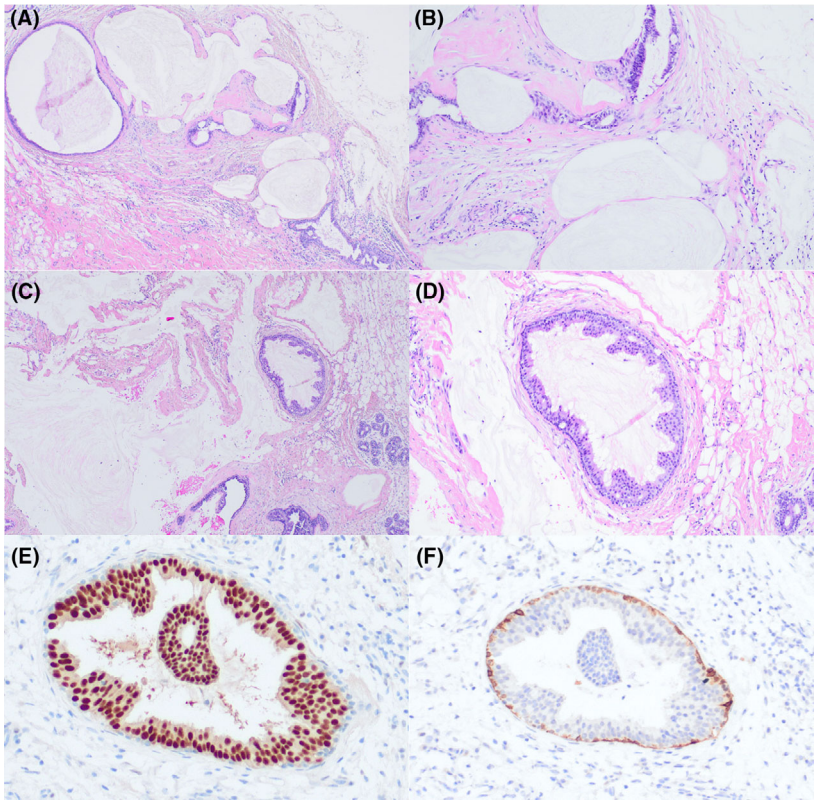

Figure 1. Mucocele-like lesion (MLL) of the breast with associated atypical ductal hyperplasia (ADH). (**A, B**) MLL with mucin-containing cysts lined by flattened to low columnar epithelium. Note the rupture of cysts with extravasation of acellular mucin into the surrounding stroma, creating mucin pools. The epithelial lining is devoid of atypia. Haematoxylin and eosin stain; original magnification ×40 (**A**), ×200 (**B**). (**C, D**) MLL with associated atypical ductal hyperplasia (ADH). The ducts show monotonous luminal epithelial proliferation with focal loss of cell polarity, mild nuclear and architectural atypia with micropapillary configuration incorporating an occasional well-defined cribriform space. Haematoxylin and eosin stain; original magnification ×100 (**C**), ×400 (**D**). (**E**) Immunohistochemical staining for oestrogen receptor (ER) exhibits diffuse, strong positive nuclear staining in the epithelial cells in the focus of ADH. Anti-ER antibody; original magnification ×200. (**F**) Immunohistochemical staining for cytokeratin 14 (CK14) demonstrates the presence of myoepithelial cells at the periphery of the ducts in focus of ADH, with staining loss in the epithelial population. Anti-CK14 antibody; original magnification ×200.

$P < 0.00001$).[24] The sensitivity and specificity for categorising a lesion as MuBC were 69.2% and 85.8%, respectively, for H&E-stained sections and 97.6% and 86.2%, respectively, for CD31 immunostains.[24] The authors concluded that this criterion enhances diagnostic accuracy in limited CNB samples, where distinguishing between MuBC and MLL can be challenging.[24]

Deeper levels and immunohistochemistry (IHC) for myoepithelial markers [p63, calponin, smooth muscle myosin heavy chain, cytokeratin (CK) 5/6, CK14] may be helpful in establishing the benign nature of free-floating epithelium within mucin. However, IHC needs to be interpreted in the appropriate context, in conjunction with the morphology. It is pertinent to note that MLLs with DCIS and ADH (without an associated invasive component) can have detached epithelium that may lack myoepithelial cells, making it impossible to ascertain the nature of these loose epithelial clusters, which should be appropriately conveyed to the clinician.

MCA (mucinous cystadenocarcinoma) may mimic MLL on radiology; however, MCA is histologically characterised by complex cyto-architectural features with tufting and papillary projections lined by tall columnar tumour cells with intracytoplasmic mucin and a triple-negative phenotype.[17] MCA needs to be distinguished from metastatic mucin secreting adenocarcinoma by clinical history, imaging and a panel of IHC markers.

MANAGEMENT AND PROGNOSIS

The behaviour of MLL depends on the associated lesions. Historically, excision has been recommended for all MLLs on CNB due to the possibility of an

© 2026 John Wiley & Sons Ltd., *Histopathology*

13652559, 0, Downloaded from https://onlinelibrary.wiley.com/doi/10.1111/his.70088 by George Mason University, Wiley Online Library on [10/03/2026]. See the Terms and Conditions (https://onlinelibrary.wiley.com/terms-and-conditions) on Wiley Online Library for rules of use; OA articles are governed by the applicable Creative Commons License

unsampled invasive carcinoma. Around 30%–45% of MLL are associated with atypical hyperplasia, most often ADH.[14] Recent literature suggests the rate of upgrade to carcinoma on excision for MLL without atypia and with radiological-pathological concordance is <3% while the upgrade rates of patients with MLL associated with atypia is 15% to 20%.[14,25–29] Meares *et al.* reported long-term clinical follow-up in 102 patients with MLL over 14.8 years where 13 patients (12.7%) developed breast cancer, at a rate similar to benign proliferative breast disease.[13] Rakha *et al.* reported a 4% rate of upgrade to in situ or invasive carcinoma in their cohort of MLL without atypia.[26] Towne *et al.* found the upgrade rate to DCIS to be twice as frequent in MLL with atypia compared to those without.[29] Sutton *et al.* evaluated 50 CNB specimens of MLLs and compared the biopsy findings with those in the subsequent excision. Among the 38 patients who underwent surgical excision, there was an overall upgrade rate of 13% to DCIS; no invasive carcinoma was identified. Notably, the risk of upgrade was found to be exclusively associated with the presence of atypia observed in the CNB specimens.[28] They recommended that patients with MLLs without atypia and no associated mass may be offered close clinical follow-up as an alternative to surgery.[28] Begum *et al.* documented the spectrum of lesions associated with mucin extravasation in breast CNB specimens and correlated them with corresponding surgical excisions. Their study found that mucin extravasation often accompanied MLLs (97%) along with CCC (84%), fibrocystic change (54%), ADH (33%) and DCIS (10%). They suggested that with close radiological-pathological correlation, open surgery may be avoided if the entire radiologic abnormality is removed with large mammotome biopsy.[30] Edelweiss *et al.* in a 22-year review of 28 cases found that epithelium associated with focal extravasated mucin was atypical in 18 cases (64%) and nonatypical in 10 cases (36%). Cancer was identified in 4 out of 28 excision specimens (14%), comprising one MuBC and three cases of DCIS. Notably, all malignancies occurred in lesions with epithelial atypia detected by CNB (4 of 18; 22%), while no cancers were found in lesions with nonatypical epithelium (0 of 10; 0%).[31]

A predominance of coarse calcifications and presence of residual targeted calcifications on imaging following CNB are associated with higher upgrade rates.[14,15]

Thus, the epithelial lesions associated with MLL need careful evaluation on limited biopsy specimens to guide further patient management. The American Society of Breast Surgeons Consensus Guideline on Concordance Assessment of Image-Guided Breast Biopsies and Management of Borderline or High-Risk Lesions (2025) recommends surgical excision only of MLLs with atypia identified on CNB.[32] Nevertheless, the management of MLL with atypia is also subject to institutional practice patterns, with few centres suggesting larger sampling such as vacuum-assisted excision biopsies as an appropriate second-line diagnostic/therapeutic approach following multidisciplinary team discussions. MLL without atypia presenting as a radiologic mass lesion should prompt surgical consultation to consider options of excision versus a more conservative approach with close follow-up.[18,28] Discussion of these cases at inter-departmental multidisciplinary conferences when possible is recommended for optimal patient management.

Mucinous carcinoma

Pure MuBC (PMuBC), previously known as colloid carcinoma, is a special subtype of invasive breast cancer associated with a favourable prognosis. Because some clinical treatment guidelines recommend only minimal systemic therapy for PMuBC (based on its favourable histologic type classification), strict criteria should be followed for the diagnosis of a pure MuBC.[33] Fewer than 5% of all invasive breast cancers have a mucinous component and only approximately 2% represent PMuBC.[34] PMuBC usually presents in postmenopausal women with a median age of 71 years.[34,35] When a mucinous carcinoma component represents between 10% and 90% of the tumour and is admixed with a non-mucinous carcinoma, most commonly IBC-NST, a mixed carcinoma is diagnosed and the specific histologic types present should be detailed.[36] Other tumour types such as ILC and invasive micropapillary carcinoma (IMPC) may represent the non-mucinous component in mixed mucinous and non-mucinous carcinomas. Patients with mixed mucinous and non-mucinous carcinomas present at a younger age than PMuBC and do not have the same favourable prognosis as PMuBC.[34]

On mammography, MuBC usually presents as a round or oval, low to high-density mass, with or without circumscribed margins, rarely associated with calcifications.[37] However, approximately 20% of MuBCs are mammographically occult. On ultrasound, MuBC often presents as a hypoechoic mass with lobulated or poorly defined margins and can mimic benign entities due to its circumscription.[38]

13652559, 0, Downloaded from https://onlinelibrary.wiley.com/doi/10.1111/his.70088 by George Mason University, Wiley Online Library on [10/03/2026]. See the Terms and Conditions (https://onlinelibrary.wiley.com/terms-and-conditions) on Wiley Online Library for rules of use; OA articles are governed by the applicable Creative Commons License

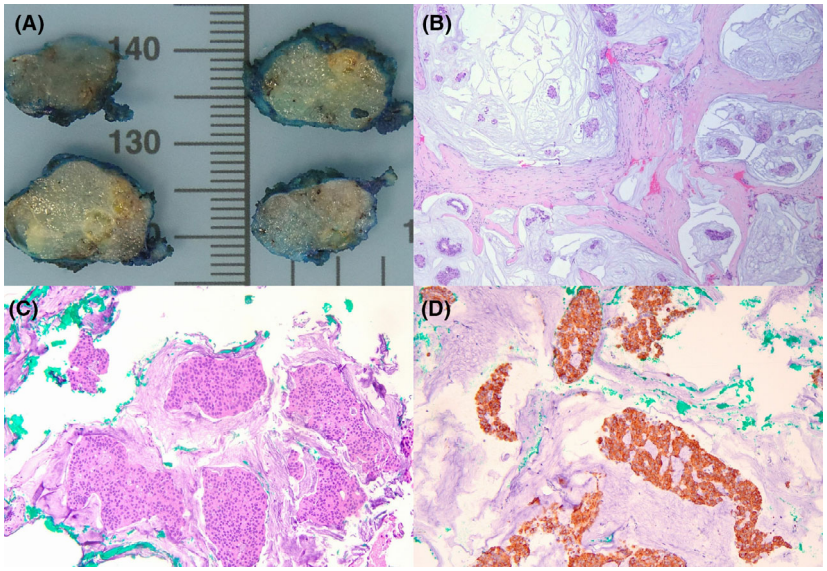

Figure 2. Mucinous breast carcinoma (MuBC). (**A**) Serial sections of an excised mucinous carcinoma show a glistening cut surface with a relatively circumscribed lobulated contour. (**B**) Type A (Paucicellular/Hypocellular) MuBC carcinoma displaying small clusters of tumour cells floating within mucin pools. The tumour cells show low nuclear grade and minimal cellular atypia. Haematoxylin and eosin stain; original magnification ×40. (**C**) Type B MuBC displaying hypercellular groups of tumour cells forming large clusters and nests of cells floating in less abundant mucin. Haematoxylin and eosin stain; original magnification ×100. (**D**) Neuroendocrine differentiation in type B MuBC is highlighted by synaptophysin immunostain. Anti-Synaptophysin antibody; original magnification ×100.

PATHOLOGY

Gross examination of MuBC shows a glistening, gelatinous nodule with pushing margins and a soft, viscous consistency (Figure 2A). Tumour size ranges from <1 cm to greater than 20 cm (average: 3 cm).[39] PMuBC is not associated with any other tumour type and the entire tumour mass (>90%) consists of invasive tumour cells freely floating in mucin. Importantly, it should be low to intermediate nuclear grade and uniformly positive for oestrogen receptor (ER). According to the current WHO classification, a high nuclear grade should exclude the diagnosis of PMuBC, which would instead be diagnosed more descriptively as "IBC-NST with mucin-production" since not all features are favourable.[33,36] Human Epidermal Growth Factor Receptor 2 (HER2) overexpression/gene amplification is also associated with worse outcomes and is not compatible with the diagnosis of PMuBC which is a favourable histologic type (see below section).

PMuBC can be classified as Type A and Type B, although these categories have no prognostic or clinical relevance, though there are transcriptomic differences, with Type B mucinous carcinoma displaying a gene expression pattern similar to that of neuroendocrine carcinoma.[40,41] Type A PMuBC, also referred to as Capella type A gelatinous or hypocellular subtype, consists of small epithelial clusters or glands having low to intermediate grade nuclear atypia suspended in abundant extracellular mucin[40] (Figure 2B). Type B PMuBC, also known as Capella type B or hypercellular subtype, contains a prominent epithelial component with larger, often branching epithelial clusters exhibiting low to at most intermediate grade nuclear atypia[40] (Figure 2C). The extracellular mucinous component is less conspicuous. The tumour cells show a variety of growth patterns, including small nests, papillary clusters, alveolar to large nests with a solid or cribriform architecture. Mixed tumours need to be documented as they do not have as good a prognosis as PMuBC.[42,43] MuBC shows a variable response to neoadjuvant therapy, with clinical and imaging assessment frequently underestimating the therapy effects due to the presence of persistent mucin pools.[44] The presence of acellular mucin in the residual tumour bed or lymph nodes in the absence of associated neoplastic epithelium is not considered as residual carcinoma in the post-neoadjuvant setting, though in the context of a primary mucinous carcinoma, careful search for residual neoplastic epithelium should be made if the post-neoadjuvant treated specimen shows extracellular mucin.[44,45]

© 2026 John Wiley & Sons Ltd., *Histopathology*

13652559, 0, Downloaded from https://onlinelibrary.wiley.com/doi/10.1111/his.70088 by George Mason University, Wiley Online Library on [10/03/2026]. See the Terms and Conditions (https://onlinelibrary.wiley.com/terms-and-conditions) on Wiley Online Library for rules of use; OA articles are governed by the applicable Creative Commons License

IMMUNOHISTOCHEMISTRY

MuBCs are uniformly positive for ER and variably positive for progesterone receptor (PR). Although HER2 overexpression and gene amplification are described in the literature in PMuBCs (<5%), the diagnosis of PMuBC should not be made for HER2 positive cancers with mucin production because it is not compatible with a favourable histologic type.[33,36,43,46] Myoepithelial cells are not found around the tumour clusters, demonstrated by lack of myoepithelial cell markers on IHC.[36] Type B tumours may show areas of neuroendocrine differentiation highlighted by IHC for neuroendocrine markers such as INSM1, chromogranin, synaptophysin and CD56[47] (Figure 2D). Proliferation rates by Ki67 should be lower than 10%–15% in a PMuBC.[36]

GENETICS

MuBC is a molecularly unique tumour with low levels of gene-copy number changes and frequent mutations in *GATA3* (24%), *KM2TC* (19%) and *MAP3K1* genes (14%).[48] Compared to IBC-NST and other low-grade ER positive breast cancers, MuBC has a lower prevalence of *PIK3CA* and *TP53* mutations as well as a lower frequency of 1q gains and 16 q losses, suggesting a distinct pathogenesis.[48] Type B tumours are reported to show higher rates of genetic alterations and a higher propensity for metastasis to lymph nodes.[34,42,43] Aberrant DNA methylation of the *MUC2* gene has been implicated as a potential cause of the abundant mucin production in these tumours.[49] In a small sampling of mixed MuBC-NST cancers, the different morphological components were clonally related and displayed genomic profiles similar to PMuBC.[47] Unlike mucinous colorectal carcinoma, MuBC is not associated with microsatellite instability[48,49]. Pareja *et al.* in their study assessing the genomic landscape of mucinous breast tumours by whole-exome sequencing, identified novel gene fusions including *OAZ1-CSNK1G2* and *RFC4-LPP* which have a potential role in ER transactivation and TGF-beta-induced breast oncogenesis, respectively.[48] While no direct genomic comparisons exist, current data suggest that PMuBC (type B) and neuroendocrine tumours (NET) of the breast share luminal features but diverge in mucin-related versus neuroendocrine pathways.[47,48]

DIFFERENTIAL DIAGNOSIS

Distinguishing paucicellular (Type A) MuBC from MLL on limited biopsy samples can be challenging. Concern for a MuBC should be mentioned in the pathology report especially in mass lesions and cases of radiologic-pathologic discordance. Multiple deeper levels and extensive sampling of the excision specimen need to be performed to rule out the presence of floating neoplastic epithelium of MuBC.[17,18,20]

IMPC is associated with a poorer prognosis than PMuBC and may cursorily mimic the latter at low magnification, particularly when the presence of intratumoral mucin is not readily appreciated.[35] IMPC exhibits characteristic tumour cell aggregates with reverse polarity, expressing MUC1 on their stromal-facing surfaces, situated within clear retraction spaces devoid of extracellular mucin. PMuBC demonstrates MUC2 expression, facilitating the production of abundant gel-forming extracellular mucin that envelops the tumour clusters, acting as a physical barrier potentially limiting tumour dissemination.[8,9] However, the immunohistochemical staining patterns for MUC1 and MUC2 frequently overlap in clinical practice, limiting their utility in distinguishing the two. The key discriminator is the presence of extracellular mucin in PMuBC. Additionally, overexpression or amplification of HER2 and high-grade nuclear atypia may be observed in IMPC but are not characteristic of PMuBC.[32,35] Extracellular mucin in MuBC, if limited in quantity, may not be immediately visible at scanning magnification.

Secretory carcinoma, a potential differential diagnosis, expresses a chimeric tyrosine kinase encoded by the *ETV6::NTRK3* fusion gene.[50] Histologically, it presents as variable glandular structures with abundant luminal and intracellular secretions having an amphophilic, pale to eosinophilic appearance, staining positive for diastase-resistant periodic acid–Schiff (PAS) with a distinct tinctorial quality and often showing fracture lines and scalloped contours at the peripheral edges.[18] However, it lacks neoplastic epithelial nests suspended in mucin pools seen in MuBC. On CNB, ruptured large glandular structures with disrupted epithelium of secretory carcinoma may be included in the differential of MuBC where the appearance of the secretions will help separate the two entities. Furthermore, in contrast to MuBC, most are triple-negative and S100-p positive.[51]

The presence of epithelial cell nests distinguishes MuBC from myxoid stromal lesions such as myxoma, nodular mucinosis and post-therapy mucinous stromal degeneration. Myxoid fibroepithelial tumours, salivary gland-like tumours and metaplastic carcinomas may be associated with prominent stromal myxoid alteration; however, they show distinct histopathological features.

© 2026 John Wiley & Sons Ltd., *Histopathology*

13652559, 0, Downloaded from https://onlinelibrary.wiley.com/doi/10.1111/his.70088 by George Mason University, Wiley Online Library on [10/03/2026]. See the Terms and Conditions (https://onlinelibrary.wiley.com/terms-and-conditions) on Wiley Online Library for rules of use; OA articles are governed by the applicable Creative Commons License

ILC with prominent signet ring cells may demonstrate focal areas of extracellular mucin (raising consideration for ILC with extracellular mucin production, see below); however, apart from presence of ILC areas, the cellularity is higher and the proportion of mucin is much less as compared to MuBC with a signet ring cell morphology.[18] In the absence of an associated in situ component, the differential diagnosis of MuBC may include metastatic mucinous carcinoma, most commonly from the gastro-intestinal or pancreatico-biliary tracts, lung and ovary.[17,18,20,22] In such cases, clinical history, imaging studies as well as a broader panel of IHC markers including site specific IHC markers (CK7, CK20, GATA3, ER, PR, CDX2, SATB2, PAX8, TTF1) will help to reach the diagnosis.

PROGNOSIS

MuBC is a favourable histologic subtype, with 10-year survival rates of over 90%.[52] The superior prognosis of PMuBC was highlighted in a retrospective analysis of more than 11,000 cases from the Surveillance, Epidemiology and End Results (SEER) database that confirmed the low rate of regional nodal involvement (12%) and excellent survival in pure MuBC patients after 20 years of follow-up (81%) in contrast to a 36% rate of lymph node metastasis and 62% survival at 20 years in patients with IBC-NST.[34] Axillary lymph node status is the most important predictor of clinical outcome, with younger patient age, larger tumour size, high nuclear grade and negative hormone receptor (HR) status being the other relevant prognostic factors associated with poorer disease-free survival.[34] The worse outcomes of tumours with high nuclear grade and HR negativity lend support to these findings being exclusion criteria for a diagnosis of MuBC which has an excellent prognosis.

Chen *et al.* reported that both pure and mixed MuBC tumours had a low and intermediate-risk recurrence score on the Oncotype Dx 21-gene test, suggesting that a considerable proportion of patients may be able to avoid chemotherapy.[53] Turashvili *et al.* analysed the 21-gene recurrence score in a cohort of 33 patients with MuBC and reported that the majority of tumours were small, grade 2 and demonstrated strong ER and PR positivity. Most cases exhibited low recurrence scores and were managed with breast-conserving surgery and adjuvant endocrine therapy. Notably, no locoregional or distant recurrences were observed at a median follow-up of 41 months.[54] MuBC also shows low levels of tumour infiltrating lymphocytes (TILs) with average counts of <5%.[55]

National Comprehensive Cancer Network (NCCN) guidelines have a separate treatment pathway for ER positive favourable histologic types, including pure mucinous, tubular and cribriform carcinomas, that emphasise tailoring therapy decisions based solely on tumour size and nodal involvement.[33] In this paradigm, pure mucinous tumours that are <1 cm in size, without nodal involvement, can be treated with surgery alone with consideration for endocrine therapy only for risk reduction. Endocrine therapy is considered for therapeutic intent in tumours that are 1–3 cm in size, and it is recommended in tumours greater than 3 cm. In tumours with nodal metastasis, endocrine therapy is recommended with or without chemotherapy based on other prognostic factors.[33]

MUCIN-PRODUCING BC WITH HIGH NUCLEAR GRADE AND/OR HER2 POSITIVITY

Histologically, PMuBC typically exhibits low-intermediate nuclear grade, is positive for ER and/or PR, and negative for HER2. While tumours with high nuclear grade and/or HER2 overexpression in PMuBCs have been reported, these high-risk features are associated with worse outcomes and are best classified as mucin-producing BCs of no special type rather than as PMuBCs (Figure 3A–C).

Prior studies have reported rates of HER2-positive mucin-producing BCs between 5.8%–9.5%.[56–60] Wei *et al.* in their study of 119 MuBCs that they considered pure (12 HER2-positive and 107 HER2-negative), found that HER2-positive mucin-producing BCs were associated with more frequent lymph node metastasis, a significantly higher clinical TNM stage, higher nuclear grade, lower ER and PR expression, and higher Ki67 expression when compared to the HER2-negative group.[60] HER2-positive mucin-producing BCs (not treated with HER2-targeted therapy) had a significantly lower overall survival (OS) rate compared to HER2-negative MuBCs. Univariate and multivariate Cox analyses also confirmed that HER2 status is an independent prognostic factor for mucin-producing BCs. Similarly, Jang *et al.* in their study of 438 mucin-producing BCs, found 21 HER2-positive tumours (4.8%), which represented a more aggressive subgroup.[61] They found the HER2-positive mucin-producing BCs to have larger tumour size, more frequent lymph node metastasis and higher nuclear and histologic grade compared to their HER2-negative counterparts. HER2-positive mucin-producing BCs also showed a higher

© 2026 John Wiley & Sons Ltd., *Histopathology*

13652559, 0, Downloaded from https://onlinelibrary.wiley.com/doi/10.1111/his.70088 by George Mason University, Wiley Online Library on [10/03/2026]. See the Terms and Conditions (https://onlinelibrary.wiley.com/terms-and-conditions) on Wiley Online Library for rules of use; OA articles are governed by the applicable Creative Commons License

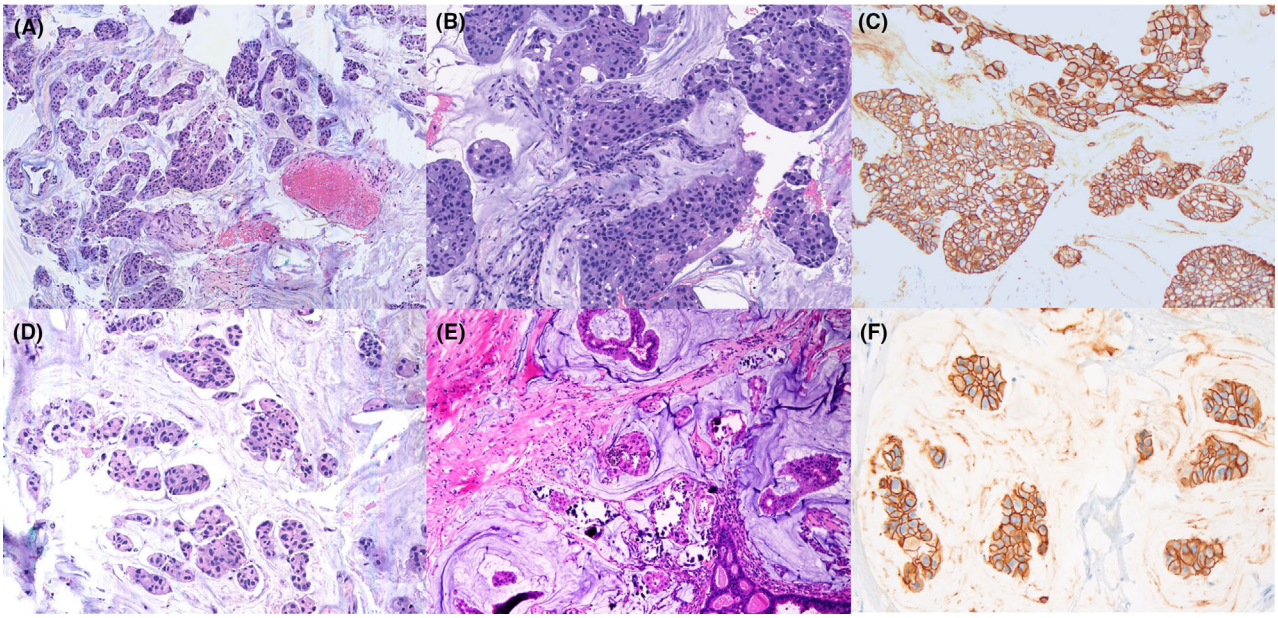

Figure 3. (**A–C**) HER2-overexpression in breast cancer with extracellular mucin. (**A**, **B**) Clusters of tumour cells floating in abundant extracellular mucin lakes. Note the hypercellular pattern with large cell clusters and moderate nuclear atypia. Haematoxylin and eosin stain; original magnification ×40 (**A**), ×200 (**B**). (**C**) Immunohistochemical staining for HER2 demonstrates strong circumferential membranous staining (3+ score) in the tumour cells within the mucin lakes. Anti-HER2 antibody; original magnification ×200. (**D–F**) Invasive breast carcinoma with micropapillary pattern and mucin production and HER2 overexpression. (**D**) Distinctive micropapillary clusters of neoplastic cells arranged in morular and floret-like structures within abundant extracellular mucin pools. Note the absence of fibrovascular cores within the micropapillary structures and the presence of clear stromal spaces around the cell clusters. The neoplastic cells demonstrate moderate to high nuclear grade with enlarged nuclei, prominent nucleoli and eosinophilic cytoplasm. Haematoxylin and eosin stain; original magnification ×40. (**E**) Morular to hollow tubular clusters of tumour cells suspended in extracellular mucin with associated psammomatous microcalcifications. Haematoxylin and eosin stain; original magnification ×200. (**F**) Characteristic basolateral HER2 immunohistochemical staining pattern observed in micropapillary carcinoma. Anti-HER2 antibody; original magnification ×400.

frequency of signet ring cells, micropapillary pattern and a higher Ki-67 labelling index. Additionally, HER2-positive mucin-producing BCs were more often negative for ER and PR. During follow-up, distant metastasis and recurrence occurred in 3 (3/21; 14.2%) HER2-positive cases. Multivariate analysis revealed that HER2 positivity and lymph node involvement were significantly associated with poorer disease-free survival, highlighting the importance of considering HER2 status in managing PMuBC. In a recent genomic analysis of stage IV MuBC, 5 out of 22 patients (23%) exhibited HER2 genomic alterations, including 3 with amplification, 1 with both amplification and mutation and 1 with mutation alone.[62] These studies affirm aggressive behaviour in HER2-positive mucin-producing BCs which impacts treatment decisions including the use of HER2 targeted therapy. It is therefore recommended that tumours with high nuclear grade and/or HER2 overexpression be classified as IBC-NST with mucin-production, to distinguish them from the conventional mucinous carcinomas associated with excellent prognosis.

MUCINOUS MICROPAPILLARY CARCINOMA

A micropapillary pattern of MuBC of the breast (MPMC) has been described as a rare histologic form of invasive carcinoma, accounting for <1% of breast cancer with hybrid features of mucinous and micropapillary invasive breast cancers (Figure 3D–F). However, this entity is not well-defined morphologically, genetically or clinically, making its diagnosis and clinical relevance challenging to discern, especially if high grade, hormone receptor negative or HER2 positive mucin-producing invasive carcinomas are excluded from the group of PMuBC.

Compared with PMuBC, series of MPMC cases report a younger age range and more aggressive behaviour with frequent lymph node metastasis and lymphovascular invasion. A retrospective cohort study by Liu *et al.* showed that MuBC with more than

13652559, 0, Downloaded from https://onlinelibrary.wiley.com/doi/10.1111/his.70088 by George Mason University, Wiley Online Library on [10/03/2026]. See the Terms and Conditions (https://onlinelibrary.wiley.com/terms-and-conditions) on Wiley Online Library for rules of use; OA articles are governed by the applicable Creative Commons License

50% micropapillary component was associated with a significantly worse prognosis than classic MuBC.[56] Although clinical characteristics are not well elucidated, prior studies show a wide age range of 28–80 years (median, 55 years).

Series examining genetic alterations in cases of MPMC describe profiles that are intermediate between PMuBC and IMPC. Some tumours show a pattern of somatic genetic alterations similar to MuBC such as the absence of *PIK3CA* mutations, whereas others display copy-number alterations in the form of recurrent chromosomal gains and losses resembling micropapillary carcinoma.[63] These findings suggest that MPMC may be an overlap entity of mucinous and micropapillary carcinoma rather than being a distinct subtype; however, the case numbers are small.[63]

Various studies have defined different cut-offs for micropapillary configuration of the neoplastic epithelium in MPMC, ranging from any percentage to more than 50% and more than 90%.[56,63,64] Sun *et al.* in their study of 161 MuBCs (129 PMuBC and 32 MPMC) used a threshold of more than 1% micropapillary pattern as the inclusion criteria for MPMC and found that the optimal cut-off value of percentage of micropapillary areas determined by the Receiver Operating Characteristic (ROC) curve was 17.5% for both tumour progression (Area Under Curve [AUC] = 0.705; sensitivity: 56.3%; specificity: 84.8%) and lymph node metastasis (AUC = 0.663; sensitivity 42.4%; specificity: 88.2%).[63] Histologically, MPMC displays hybrid mucinous and micropapillary features; the latter consisting of hollow tubular rings with crisp or serrated peripheral borders or micropapillary clusters of tumour cells with scalloped edges and hobnailed to vacuolated cytoplasm floating in extracellular mucin, showing reverse polarity and outward apical snouts. Psammomatous calcifications and adjacent micropapillary DCIS are frequently seen.

Immunohistochemistry (IHC) for MUC1 was previously used to confirm the micropapillary pattern in MuBC by highlighting the reverse-polarity staining pattern. However, the significant overlap in MUC1 expression between micropapillary and PMuBC limits its utility in routine clinical practice.[63,65] Most authors do not support using EMA to define MPMC because the "inside out" pattern of staining is also frequently seen in PMuBC. MPMC is usually HR positive, though it displays higher rates of HER2 amplification compared to PMuBC. As in IMPC, a basolateral expression of HER2 IHC should be regarded as equivocal and reflexed to fluorescent in situ hybridisation (FISH) testing.[65]

Summarising previous studies comparing PMuBC with MPMC, several factors have been linked to a poorer prognosis: micropapillary architecture exceeding 50%, intermediate to high nuclear grade, high Ki67 levels (>15%) and HER2 amplification.[56,58,60,61,63,65] Since the presence of mixed non-mucinous carcinoma, high nuclear grade and HER2 amplification are also considered high risk and are not compatible with a diagnosis of PMuBC, whether the presence of the micropapillary pattern alone without accompanying adverse features is independently prognostic is uncertain. It is recommended that the presence of the micropapillary pattern be mentioned if prominent, but there is insufficient evidence for it to be separately classified as a distinct entity or as a specific subtype of PMuBC.

Mucinous cystadenocarcinoma

Primary MCA of the breast is an exceedingly rare tumour included as a subtype of primary breast carcinoma in the 5th edition of WHO classification of breast tumours.[66] It was first described by Koenig and Tavassoli in 1998 with only a handful of cases reported in the literature, mostly in Asian women.[67] It presents in the postmenopausal age group with a median age of 65 years.[66,68] MCA is characterised by cystic spaces lined by neoplastic epithelium with prominent papillary architecture and tall columnar, pseudostratified cells having abundant intra- and extracellular mucin, reminiscent of pancreatobiliary or ovarian MCA (Figure 6A).[66–69] MCA is typically negative for ER, PR and HER2, and expresses CK7, CK20 (patchy) and mucin markers (MUC5AC, MUC6)[69,70] It is critical to distinguish primary MCA of the breast from metastatic mucinous adenocarcinoma using clinical findings, imaging, histology and a panel of IHC markers (including CK7, CK20, GATA3, CDX2, SATB2, TTF1, PAX8, WT1).[67–70] Associated papillary DCIS with/without mucin may be seen in the primary breast tumours. Although no driver mutations have been identified in MCA, Chen *et al.* identified a *PIK3CA* hot-spot mutation in one case of MCA by whole genome next-generation sequencing.[71] In contrast to pancreatic and ovarian counterparts, no *KRAS, NRAS, BRAF* or *AKT* mutations have been reported.[71] Next-generation sequencing of four cases by Zheng *et al.* revealed recurrent mutations in *TP53*, *PIK3CA, AKT* (notably *AKT1 E17K*), *PTEN* and *RB1*, with variable concordance between gene mutations and protein expression for AKT, PTEN and PIK3CA. No germline mutations,

© 2026 John Wiley & Sons Ltd., *Histopathology*

13652559, 0, Downloaded from https://onlinelibrary.wiley.com/doi/10.1111/his.70088 by George Mason University, Wiley Online Library on [10/03/2026]. See the Terms and Conditions (https://onlinelibrary.wiley.com/terms-and-conditions) on Wiley Online Library for rules of use; OA articles are governed by the applicable Creative Commons License

PDL-1 expression, or MSI-H status were detected.[72] The biological behaviour of MCA is reportedly favourable despite having a high proliferation index and triple-negative biomarker status. However, most of the previously reported cases had a short clinical follow-up.[68–70]

DCIS with intraluminal mucin

DCIS is occasionally associated with conspicuous mucin production. This may be seen in conventional patterns of DCIS, such as micropapillary or cribriform, or in solid papillary carcinoma (SPC) in situ. DCIS that is associated with mucinous carcinoma frequently contains intraluminal mucin with neovascularisation.[24] Associated in situ component in the form of mucinous DCIS is identified in 60%–75% of MuBC.[18]

Solid papillary carcinoma

SPC is a distinctive form of papillary carcinoma characterised by closely apposed expansile, cellular tumour nodules. SPC is thought to be a precursor of the type B pattern of MuBC, primarily found in elderly women, arising in the central region of the breast.[73,74] Grossly, the tumour consists of single or multiple circumscribed nodules with a fleshy to firm consistency. SPC is characterised by circumscribed solid nodules that are variably sized, ranging from small and DCIS-like to expansile masses with delicate, hyalinised fibrovascular cores, better appreciated on high power magnification (Figure 4).[74,75] The neoplastic proliferation is low to intermediate grade and commonly displays a streaming appearance resembling florid usual ductal hyperplasia (UDH).[76] The tumour cells may be ovoid, spindled with nuclear grooves, or plasmacytoid with eosinophilic cytoplasm and eccentric nuclei. Scattered tumour cells may contain intracytoplasmic mucin vacuoles.

Invasion in SPC is characterised by the presence of irregular jig-saw shaped epithelial islands with jagged contours and desmoplastic stroma. Immunohistochemical stains for myoepithelial cells may not always be helpful in the differential diagnosis of invasive versus non-invasive SPC, as the latter may lack a myoepithelial cell layer, though myoepithelial rims are often identified around SPC in situ.[73–75] A conventional invasive carcinoma is found in

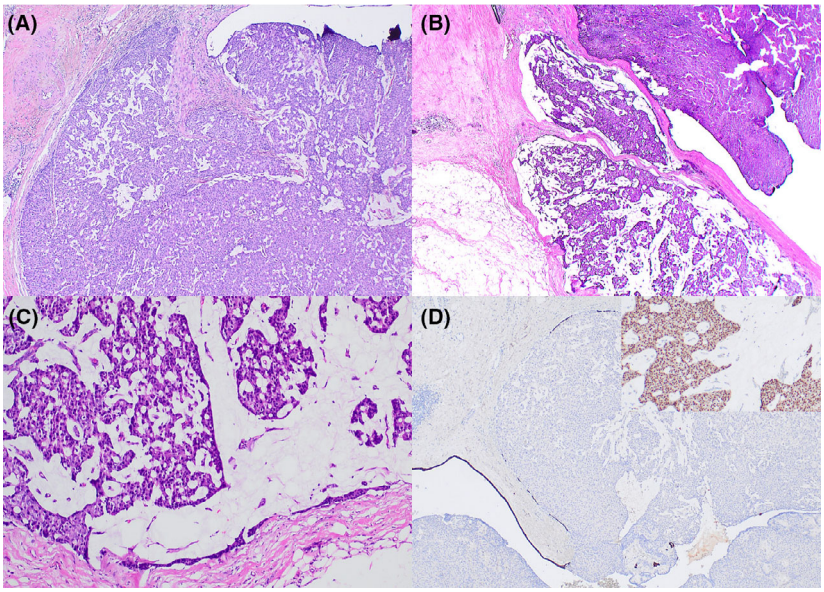

Figure 4. Solid papillary carcinoma (SPC) in situ with mucin. (**A**) SPC with well-circumscribed nodular architecture composed of monomorphic cells with low-grade nuclear features arranged around delicate fibrovascular cores. Haematoxylin and eosin stain; original magnification ×40. (**B**) Notable extracellular mucin pools are evident in some of the tumour nests, which may raise concern for an associated MuBC. The tumour exhibits smooth, pushing borders. Haematoxylin and eosin stain; original magnification ×100. (**C**) The neoplastic cells display a uniform, monotonous appearance with oval nuclei, fine chromatin and inconspicuous nucleoli. Haematoxylin and eosin stain; original magnification ×200. (**D**) Immunohistochemical staining for cytokeratin 14 (CK14) demonstrating cytoplasmic positivity of myoepithelial cells at the periphery of the lesion while being absent in the central portion. Anti-CK14 antibody; original magnification ×40. (**D** Inset) ER immunohistochemistry showing strong nuclear positivity in the majority of tumour cells. Anti-ER antibody; original magnification ×100.

© 2026 John Wiley & Sons Ltd., *Histopathology*

13652559, 0, Downloaded from https://onlinelibrary.wiley.com/doi/10.1111/his.70088 by George Mason University, Wiley Online Library on [10/03/2026]. See the Terms and Conditions (https://onlinelibrary.wiley.com/terms-and-conditions) on Wiley Online Library for rules of use; OA articles are governed by the applicable Creative Commons License

approximately half of the cases which may be mucinous, ductal and, less commonly, lobular.[75] Pathologic staging is based on the size of the frankly invasive component. SPCs are generally HR positive and HER2 negative. Neuroendocrine differentiation is frequently seen, especially when associated with a mucinous component.[77] SPC shows few copy-number aberrations compared to IBC-NST. *PIK3CA* mutations are found in 43% of cases.[78] While SPC without invasion is considered to have a good prognosis, the prognosis of SPC with invasion is dictated by the invasive component.[74,76]

ILC with extracellular mucin (ILCEM)

ILC with extracellular mucin production (ILCEM), first described by Rosa *et al.* in 2009, is a rare, emerging histologic subtype of ILC with tumour cells displaying a lobular (instead of ductal/NST) phenotype.[79] It usually presents as a large mass (more than 2 cm) in the postmenopausal age group. Histologically, the tumour is characterised by a typical ILC component as well as single cells or clusters of cells floating within mucin (Figure 5). The mucinous component in ILCEM may show pseudo-glandular, solid, trabecular or pseudo-cribriform architecture which may be misinterpreted as of ductal phenotype.[80,81] The nuclear grade in ILCEM can be high (grade 2 to 3) with non-classical lobular features such as signet-ring cell change, pleomorphic features, apocrine cytology and solid growth pattern along with HER2 expression on IHC which may cause further diagnostic challenge.[82–84] Co-existent LCIS is identified adjacent to the classic ILC in the majority of cases.[80] Loss of membrane expression or aberrant cytoplasmic localisation of E-cadherin with cytoplasmic localisation of p120 catenin on IHC is seen in both the non-mucinous and mucinous components of the invasive carcinoma and in the LCIS component. All previously reported tumours were hormone receptor-positive, with a higher rate of HER2 positivity than seen in classic ILC and PMuBC.[81,82] Triple-negative ILCEM has not been formally reported though a case was recently described in an abstract (Lab Invest 105, 2025, 102339). While evaluating mucin expression patterns, Yu *et al.* found MUC1 immunoreactivity in ILCEM in contrast to PMuBC which shows MUC2 expression on IHC.[84]

Soong *et al.* performed next-generation sequencing interrogating the full coding sequences of 447 genes for mutations, copy number variations as well as gene rearrangements in 13 cases of ILCEM which revealed genetic alterations consistent with a lobular

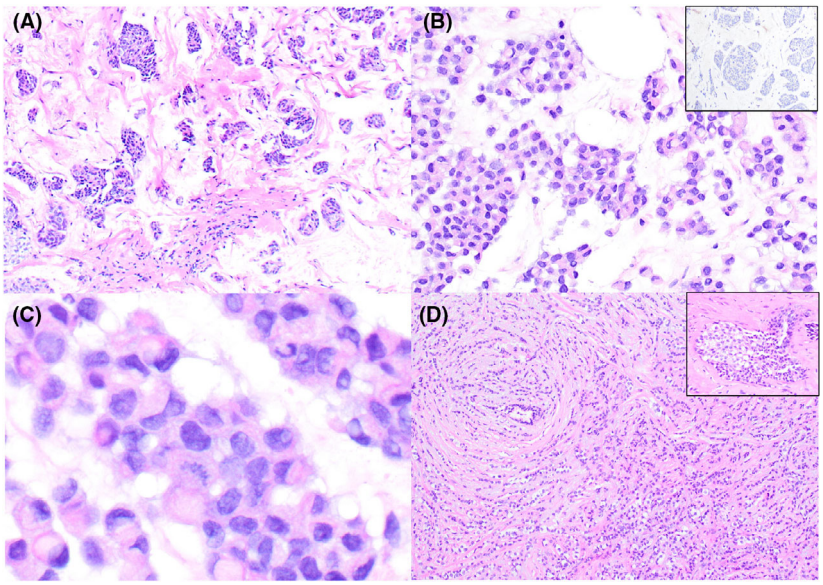

Figure 5. Invasive lobular carcinoma with extracellular mucin (ILCEM). (**A, B**) Nests of tumour cells suspended in extracellular mucin pools. Haematoxylin and eosin stain; original magnification ×40, ×100. (**B**, inset) The tumour cells show loss of E-cadherin expression. Anti-E-cadherin antibody; original magnification ×40. (**C**) Tumour cells appear relatively monomorphic with plasmacytoid to signet-ring appearances. Haematoxylin and eosin stain; original magnification ×400. (**D**) Associated ILC is seen in one of the cores. Haematoxylin and eosin stain; original magnification ×40. (**D** inset) Adjacent breast parenchyma shows a focus of lobular carcinoma in situ (LCIS). Haematoxylin and eosin stain; original magnification ×200.

© 2026 John Wiley & Sons Ltd., *Histopathology*

13652559, 0, Downloaded from https://onlinelibrary.wiley.com/doi/10.1111/his.70088 by George Mason University, Wiley Online Library on [10/03/2026]. See the Terms and Conditions (https://onlinelibrary.wiley.com/terms-and-conditions) on Wiley Online Library for rules of use; OA articles are governed by the applicable Creative Commons License

phenotype.[85] They found alterations of *CDH1* at the gene level in 12 cases (12/13; 92%) and concurrent *CDH1* mutations and 16q loss in 11 cases (11/13; 84.6%). ILCEM harboured *PIK3CA* (3/13; 23%), *RUNX1* (2/13; 15%), *AKT1* (2/13; 15%) and *PTEN* (1/13; 7.7%) mutations as well as *FOXA1* amplifications coupled with *GATA3* amplifications (3/13; 23%) which are more common in luminal A invasive ductal carcinoma (IBC-NST).[85] ILCEM with recurrences during follow-up harboured additional biologically relevant genomic alterations (*ERBB2, ERBB3, TP53, POLQ, CCND1* and *FGFR1*), which may contribute to their aggressive clinico-pathologic features.[84] They also found *ERBB2* or *ERBB3* alterations as well as *TP53* mutations in ILCEM with pleomorphic features.[85] Mutations in *POLQ*, a gene encoding DNA polymerase theta involved in DNA repair pathway response to double strand breaks, are associated with high tumour grade and poorer survival in breast cancer. Of the three patients in their series with death due to disease, one patient had a *POLQ*-pathogenic mutation while two others had *TP53* mutations.[85]

The differential diagnosis of ILCEM is broad and includes mixed mucinous and non-mucinous carcinoma, metaplastic matrix-producing carcinoma, PMuBC-type B, SPC with extracellular mucin and metastatic signet-ring cell carcinoma. Most of these tumours show membranous expression for E-cadherin on IHC.[80–83] Clinical history and imaging correlation will help in distinguishing a primary tumour from metastasis to the breast. In the absence of an in situ component, a metastasis of gastric origin should be considered in ER negative lobular-like carcinoma with prominent signet-ring cell morphology. ILCEM has a worse prognosis than classic ILC and PMuBC. Higher stage at presentation, postmenopausal age, axillary lymph node involvement, and solid, pleomorphic and signet-ring cell morphology in ILCEM are associated with worse prognosis, supported by their aggressive molecular signatures.[85] ILCEM with omental metastasis may show mucinous omental caking or pseudomyxoma peritonei.

Salivary gland type tumours of the breast with mucinous features

Mucoepidermoid carcinoma (MEC) of the breast is an extremely rare malignant tumour resembling its salivary gland counterpart in histology and molecular genetics.[86] Histologically, it comprises variable proportions of mucinous, epidermoid and intermediate cells. Low-grade MEC is composed largely of cystic spaces lined by flat-to-columnar mucinous epithelium with abundant extracellular mucin which may raise the differential diagnosis of a true mucinous breast tumour. Careful evaluation for the presence of associated squamoid/ epidermoid cells is helpful in differentiating the two.[86] IHC for CK7 is positive in the mucinous cells, and CK5/6 and CK14 are positive in the epidermoid cells imparting a zonation pattern while MuBC is diffusely and strongly positive for CK7.[87] Despite being triple-negative, MEC of the breast retains the GATA3 and mammaglobin positivity observed in other breast tumours. MECs of the breast, especially the low-grade tumours, harbour the *t*(11;19) translocation, resulting in fusion of *CRTC1* (*MECT1*) and *MAML2* which is typical of low-grade salivary gland MEC.[88] Prognosis depends on the grade of MEC with high-grade tumours being associated with axillary lymph node metastasis.[87]

Mimics of mucinous breast lesions

Several mesenchymal and fibroepithelial, biphasic or salivary gland-like lesions of the breast are accompanied by an increase in stromal ground substance or connective tissue mucins mimicking extracellular mucin production by epithelial cells. A careful histological examination and search for diagnostic clues will help to clinch the diagnosis, although this may prove challenging in certain scenarios with limited CNB samples. In such cases, a multidisciplinary discussion helps in narrowing the differential diagnoses. These lesions include nodular mucinosis, myxoid fibroadenoma (Figure 6B), phyllodes tumour, salivary gland-like lesions such as adenoid cystic carcinoma and pleomorphic adenoma (Figure 6D), myxoma, myxoid myofibroblastoma and metaplastic carcinoma (Figure 6C).[17,18,22]

Nodular mucinosis is a very rare non-neoplastic lesion found in the subareolar region of young women.[89] It consists of multiple, well-circumscribed nodules composed of bland spindle cells in an abundant myxoid matrix (positive for acidic mucin; alcian blue-pH 2.5 and Hale's colloidal iron and negative for PAS). There is no epithelial component in nodular mucinosis, which helps to distinguish it from MLL or MuBC. MLL and MuBC have an associated epithelial component, and the character of the mucin is neutral or weakly acidic (positive for PAS stain). Fibroadenoma with myxoid stroma, nerve sheath tumours with myxoid degeneration and Carney syndrome related breast myxoma are also included in the differential diagnosis of nodular mucinosis.[17,18,22]

© 2026 John Wiley & Sons Ltd., *Histopathology*

13652559, 0, Downloaded from https://onlinelibrary.wiley.com/doi/10.1111/his.70088 by George Mason University, Wiley Online Library on [10/03/2026]. See the Terms and Conditions (https://onlinelibrary.wiley.com/terms-and-conditions) on Wiley Online Library for rules of use; OA articles are governed by the applicable Creative Commons License

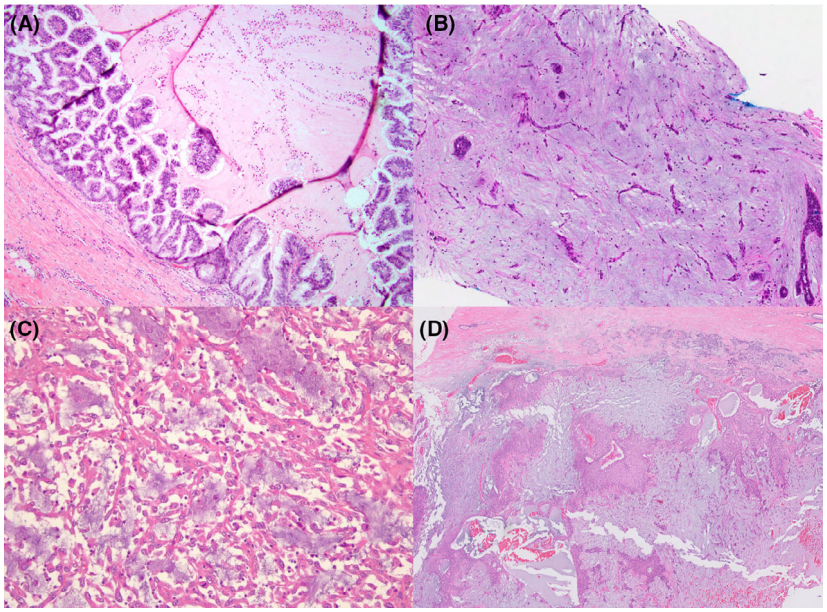

Figure 6. Miscellaneous mucinous breast lesions. (**A**) Mucinous cystadenocarcinoma shows papillary fronds arising from the wall of a mucin-filled cystically dilated neoplastic duct, with cells containing cytoplasmic mucin and basally oriented nuclei. Haematoxylin and eosin stain; original magnification ×100. (**B**) Myxoid fibroadenoma. Core biopsy of a myxoid fibroadenoma shows an almost watery myxoid stroma. Haematoxylin and eosin stain; original magnification ×100. (**C**) Metaplastic spindle cell carcinoma shows myxoid ground substance among the malignant spindle cells. Haematoxylin and eosin stain; original magnification ×200. (**D**) Pleomorphic adenoma. Scanning magnification of a breast pleomorphic adenoma shows epithelial islands in myxoid matrix hosting narrow strands of epithelial and myoepithelial cells. Haematoxylin and eosin stain; original magnification ×100.

Myxoma is a benign mesenchymal tumour, which rarely develops in the breast. It is either sporadic or inherited as part of Carney's complex.[90,91] Histologically, myxoma is a circumscribed hypocellular tumour having stellate to plump spindle cells with vesicular nuclei and scant cytoplasm embedded in a myxoid stroma. The pink myxoid tissue is positive for Alcian blue and Hale's colloidal iron as it is composed of acid mucopolysaccharides and is negative for PAS stain.

Adenoid cystic carcinoma is a rare histologic form of triple-negative breast carcinoma of the breast analogous to its salivary gland counterpart.[86,92] Classic adenoid cystic carcinoma features epithelial and myoepithelial cells in tubular, cribriform to solid patterns. Nests of tumour cells in a rigid cribriform configuration within myxoid oedematous stroma may on cursory glance superficially resemble mucinous carcinoma. The triple-negative phenotype with positivity for CD117 and MYB on IHC will help resolve the dilemma.[92] Classic adenoid cystic carcinoma is an indolent tumour with excellent prognosis.

Pleomorphic adenoma is an epithelial-myoepithelial neoplasm with stromal components. The epithelial cells are cuboidal to columnar with bland nuclei, arranged in tubules, cords, or sheets. Myoepithelial cells may appear polygonal, plasmacytoid, fusiform, or stellate, with small nuclei and clear to eosinophilic cytoplasm, dispersed in the stroma. The stroma ranges from loose myxoid to chondroid (Figure 6D). Paucicellular lesions with abundant myxoid stroma may mimic PMuBC on biopsy. Jaffer *et al.* analysed 8 PMuBC cases and found that all showed extracellular mucin positivity with alcian blue (pH 1.0 and 2.5) staining, which was resistant to hyaluronidase treatment unlike pleomorphic adenoma, where staining was lost after hyaluronidase digestion.[93]

Matrix-producing metaplastic carcinoma with an abrupt transition from the epithelial to the mesenchymal components without the presence of intervening spindle cells can display prominent acellular myxoid areas raising the differential of MuBC on CNB (Figure 6C).[94] Larger tumour size, presence of malignant mesenchymal components including malignant chondroid elements, high nuclear grade and triple-negative phenotype are features of matrix-producing metaplastic carcinoma. These tumours show acidic, sulphated, mucopolysaccharide-rich stroma (positive for alcian blue and Hale's colloidal iron) in contrast to mucin secreting epithelial lesions.

© 2026 John Wiley & Sons Ltd., *Histopathology*

13652559, 0, Downloaded from https://onlinelibrary.wiley.com/doi/10.1111/his.70088 by George Mason University, Wiley Online Library on [10/03/2026]. See the Terms and Conditions (https://onlinelibrary.wiley.com/terms-and-conditions) on Wiley Online Library for rules of use; OA articles are governed by the applicable Creative Commons License

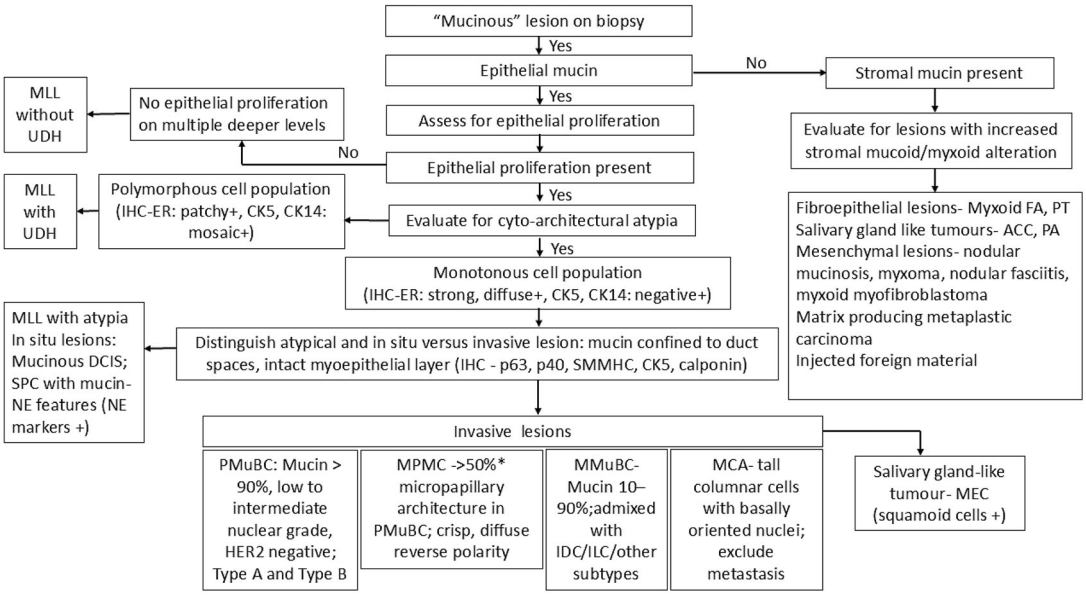

Abbreviations: *MLL: Mucocele like lesion; UDH: Usual ductal hyperplasia; ER: Estrogen receptor; DCIS: ductal carcinoma in situ; SPC: Solid papillary carcinoma; NE: neuroendocrine; IHC: immunohistochemistry; PMuBC: pure mucinous breast carcinoma; MPMC: micropapillary breast carcinoma; MMuBC: mixed-mucinous breast carcinoma; IDC: invasive ductal carcinoma; ILC: invasive lobular carcinoma; MCA: mucinous cystadenocarcinoma; MEC: mucoepidermoid carcinoma; FA: fibroadenoma; PT: phyllodes tumour; ACC: adenoid cystic carcinoma; PA: pleomorphic adenoma*

MPMC: Micropapillary clusters of tumour cells within mucin pools (>50%); may have high nuclear grade; LVI is common

Figure 7. An algorithm-based approach to mucinous breast lesions on biopsy specimens. The algorithm provides a stepwise approach to diagnostic evaluation of mucinous breast lesions encountered in histological specimens.

Other mimics of extracellular mucin include injected foreign material marking a CNB site, and leakage from a silicone implant inserted for breast augmentation. Injected foreign substance in breast augmentation may produce a histological appearance of extracellular mucin-like material. However, it shows a different tinctorial quality with the polyacrylamide content associated with a violaceous glassy hue, with surrounding chronic inflammation, fibrosis and foreign body-type giant-cell reaction.[17]

Summary

Mucinous lesions of the breast include a heterogeneous group of entities which feature extracellular mucin production, with variable clinical behaviour (Table 1). An algorithmic approach to the diagnosis of mucinous breast lesions is suggested in Figure 7. Awareness of their histological characteristics and pitfalls in limited material will ensure accurate diagnosis for optimal management. The most appropriate classification of MuBC with micropapillary pattern may evolve with additional studies. High nuclear grade and/or HER2 overexpression in mucin-producing invasive carcinomas should not be regarded as conventional MuBC due to their association with a worse prognosis.

Author contributions

SM searched the literature and wrote the manuscript. TPH supervised the manuscript content and editing. All authors read, provided input and approved the final manuscript.

Acknowledgements

EB and HYW are supported in part by a Cancer Center Support Grant of the National Institutes of Health/National Cancer Institute (Grant No. P30CA008748). The administrative assistance of Ms Diyana Bte Md Nasir from the Singapore Breast Surgery Centre Singapore is gratefully acknowledged.

Funding information

The authors did not receive support from any organisation for the submitted work.

© 2026 John Wiley & Sons Ltd., *Histopathology*

13652559, 0, Downloaded from https://onlinelibrary.wiley.com/doi/10.1111/his.70088 by George Mason University, Wiley Online Library on [10/03/2026]. See the Terms and Conditions (https://onlinelibrary.wiley.com/terms-and-conditions) on Wiley Online Library for rules of use; OA articles are governed by the applicable Creative Commons License

Conflict of interest

The authors have no relevant financial or non-financial interests to disclose.

Data availability statement

The original contributions presented in the study are included in the article material. Further inquiries can be directed to the corresponding author.

References

1. Suvarna KS, Layton C, Bancroft JD eds. *Bancroft's theory and practice of histological techniques*. 8th ed. London: Elsevier, 2019.
2. Gendler SJ, Spicer AP. Epithelial mucin genes. *Annu. Rev. Physiol.* 1995; **57**; 607–634.
3. Kang Y, Park H, Choe BH, Kang B. The role and function of mucins and its relationship to inflammatory bowel disease. *Front. Med. (Lausanne)* 2022; **9**; 848344.
4. Dhanisha SS, Guruvayoorappan C, Drishya S, Abeesh P. Mucins: structural diversity, biosynthesis, its role in pathogenesis and as possible therapeutic targets. *Crit. Rev. Oncol. Hematol.* 2018; **122**; 98–122.
5. Kufe DW. Mucins in cancer: function, prognosis and therapy. *Nat. Rev. Cancer* 2009; **9**; 874–885.
6. Hattrup CL, Gendler SJ. MUC1 alters oncogenic events and transcription in human breast cancer cells. *Breast Cancer Res.* 2006; **8**; R37.
7. Mukhopadhyay P, Chakraborty S, Ponnusamy MP, Lakshmanan I, Jain M, Batra SK. Mucins in the pathogenesis of breast cancer: implications in diagnosis, prognosis and therapy. *Biochim. Biophys. Acta* 2011; **1815**; 224–240.
8. Matsukita S, Nomoto M, Kitajima S *et al*. Expression of mucins (MUC1, MUC2, MUC5AC and MUC6) in mucinous carcinoma of the breast: comparison with invasive ductal carcinoma. *Histopathology* 2003; **42**; 26–36.
9. Rakha EA, Boyce RW, Abd El-Rehim D *et al*. Expression of mucins (MUC1, MUC2, MUC3, MUC4, MUC5AC and MUC6) and their prognostic significance in human breast cancer. *Mod. Pathol.* 2005; **18**; 1295–1304.
10. Couchman JR, Pataki CA. An introduction to proteoglycans and their localization. *J. Histochem. Cytochem.* 2012; **60**; 885–897.
11. Rosen PP. Mucocele-like tumour of the breast. *Am. J. Surg. Pathol.* 1986; **10**; 464–469.
12. Fadare O, Mariappan MR. Mucocele-like tumor and columnar cell hyperplasia of the breast occurring in a morphologic continuum. *J. Med. Case Rep.* 2008; **2**; 138–141.
13. Meares AL, Frank RD, Degnim AC *et al*. Mucocele-like lesions of the breast: a clinical outcome and histologic analysis of 102 cases. *Hum. Pathol.* 2016; **49**; 33–38.
14. Ha D, Dialani V, Mehta TS, Keefe W, Iuanow E, Slanetz PJ. Mucocele-like lesions in the breast diagnosed with percutaneous biopsy: is surgical excision necessary? *AJR Am. J. Roentgenol.* 2015; **204**; 204–210.
15. Kim JY, Han BK, Choe YH, Ko YH. Benign and malignant mucocele-like tumors of the breast: mammographic and sonographic appearances. *AJR Am. J. Roentgenol.* 2005; **185**; 1310–1316.
16. Leibman AJ, Staeger CN, Charney DA. Mucocele-like lesions of the breast: mammographic findings with pathologic correlation. *Am. J. Roentgenol.* 2006; **186**; 1356–1360.
17. Tan PH, Tse GM, Bay BH. Mucinous breast lesions: diagnostic challenges. *J. Clin. Pathol.* 2008; **61**; 11–19.
18. Harrison BT, Dillon DA. An update on mucinous lesions of the breast. *Surg. Pathol. Clin.* 2018; **11**; 61–90.
19. Hamele-Bena D, Cranor ML, Rosen PP. Mammary mucocele-like lesions. *Am. J. Surg. Pathol.* 1996; **20**; 1081–1085.
20. Singh K, Karamchandani DM. Mucinous lesions of the breast: potpourri of old and new. *Diagn. Histopathol.* 2020; **26**; 69–75.
21. Shin SJ, Rosen PP. Carcinoma arising from preexisting pregnancy-like and cystic hypersecretory hyperplasia lesions of the breast: a clinicopathologic study of 9 patients. *Am. J. Surg. Pathol.* 2004; **28**; 789–793.
22. Joneja U, Palazzo J. The Spectrum of mucinous lesions of the breast. *Arch. Pathol. Lab Med.* 2023; **147**; 19–29.
23. Van Diest PJ, Pinder S, Fox SB *et al*. Ductal carcinoma in situ. In: WHO Classification of Tumours Editorial Board ed. *Breast tumours. WHO Classification of Tumours*. 5th ed. Vol **2**. Lyon: IARC, 2019.
24. Onken AM, Collins LC, Schnitt SJ. Mucin neovascularization as a diagnostic aid to distinguish mucinous carcinomas from mucocele-like lesions in breast Core needle biopsies. *Am. J. Surg. Pathol.* 2022; **46**; 637–642.
25. Zhang G, Ataya D, L Lebda P, Calhoun BC. Mucocele-like lesions diagnosed on breast core biopsy: low risk of upgrade and subsequent carcinoma. *Breast J.* 2018; **24**; 314–318.
26. Rakha EA, Shaaban AM, Haider SA *et al*. Outcome of pure mucocele-like lesions diagnosed on breast core biopsy. *Histopathology* 2013; **62**; 894–898.
27. Diorio C, Provencher L, Morin J *et al*. Is there an upgrading to malignancy at surgery of mucocele-like lesions diagnosed on percutaneous breast biopsy? *Breast J.* 2016; **22**; 173–179.
28. Sutton B, Davion S, Feldman M, Siziopikou K, Mendelson E, Sullivan M. Mucocele-like lesions diagnosed on breast core biopsy: assessment of upgrade rate and need for surgical excision. *Am. J. Clin. Pathol.* 2012; **138**; 783–788.
29. Towne WS, Michaels AY, Ginter PS. Mucocele-like lesion of the breast diagnosed on Core biopsy. *Arch. Pathol. Lab Med.* 2022; **146**; 213–219.
30. Begum SM, Jara-Lazaro AR, Thike AA *et al*. Mucin extravasation in breast core biopsies-clinical significance and outcome correlation. *Histopathology* 2009; **55**; 609–617.
31. Edelweiss M, Corben AD, Liberman L *et al*. Focal extravasated mucin in breast core needle biopsies: is surgical excision always necessary? *Breast J.* 2013; **19**; 302–309.
32. Consensus guideline on concordance assessment of image-guided breast biopsies and management of benign or high-risk lesions. 2025. The American Society of Breast Surgeons. https://www.breastsurgeons.org/resources/statements.
33. Gradishar WJ, Moran MS, Abraham J *et al*. Breast cancer, version 3.2024, NCCN clinical practice guidelines in oncology. *J. Natl. Compr. Cancer Netw.* 2024; **22**; 331–357.
34. Di Saverio S, Gutierrez J, Avisar E. A retrospective review with long term follow up of 11,400 cases of pure mucinous breast carcinoma. *Breast Cancer Res. Treat.* 2008; **111**; 541–547.
35. Hoda SA, Brogi E, Koerner FC. *Rosen's breast pathology*. 5th ed. Philadelphia (PA): Lippincott Williams & Wilkins, 2021.
36. Brogi E, Wen HY, Desmedt C, Reis-Filho JS, Schmitt F. Mucinous carcinoma. In: *WHO Classification of Tumours Editorial Board. Breast tumours. WHO Classification of Tumours*. 5th ed. Vol **2**. Lyon: IARC, 2019.

© 2026 John Wiley & Sons Ltd., *Histopathology*

13652559, 0, Downloaded from https://onlinelibrary.wiley.com/doi/10.1111/his.70088 by George Mason University, Wiley Online Library on [10/03/2026]. See the Terms and Conditions (https://onlinelibrary.wiley.com/terms-and-conditions) on Wiley Online Library for rules of use; OA articles are governed by the applicable Creative Commons License

37. Memis A, Ozdemir N, Parildar M, Ustun EE, Erhan Y. Mucinous (colloid) breast cancer: mammographic and US features with histologic correlation. *Eur. J. Radiol.* 2000; **35**; 39–43.
38. Chopra S, Evans AJ, Pinder SE *et al*. Pure mucinous breast cancer-mammographic and ultrasound findings. *Clin. Radiol.* 1996; **51**; 421–424.
39. Rosen PP, Oberman HA. *Tumors of the mammary gland*. Vol. **7**. Washington, DC: Armed Forces Institute of Pathology, 1993.
40. Weigelt B, Horlings HM, Kreike B *et al*. Refinement of breast cancer classification by molecular characterization of histological special types. *J. Pathol.* 2008; **216**; 141–150.
41. Capella C, Eusebi V, Mann B, Azzopardi JG. Endocrine differentiation in mucoid carcinoma of the breast. *Histopathology* 1980; **4**; 613–630.
42. Rasmussen BB, Rose C, Christensen IB. Prognostic factors in primary mucinous carcinoma. *Am. J. Clin. Pathol.* 1987; **87**; 155–160.
43. Komaki K, Sakamoto G, Sugano H, Morimoto T, Monden Y. Mucinous carcinoma of the breast in Japan. A prognostic analysis based on morphologic features. *Cancer* 1988; **61**; 989–996.
44. Didonato R, Shapiro N, Koenigsberg T, D'Alfonso T, Jaffer S, Fineberg S. Invasive mucinous carcinoma of the breast and response patterns after neoadjuvant chemotherapy (NAC). *Histopathology* 2018; **72**; 965–973.
45. Provenzano E, Bossuyt V, Viale G *et al*. Standardization of pathologic evaluation and reporting of postneoadjuvant specimens in clinical trials of breast cancer: recommendations from an international working group. *Mod. Pathol.* 2015; **28**; 1185–1201.
46. Komenaka IK, El-Tamer MB, Troxel A *et al*. Pure mucinous carcinoma of the breast. *Am. J. Surg.* 2004; **187**; 528–532.
47. Scopsi L, Andreola S, Pilotti S *et al*. Mucinous carcinoma of the breast. A clinicopathologic, histochemical and immunocytochemical study with special reference to neuroendocrine differentiation. *Am. J. Surg. Pathol.* 1994; **18**; 702–711.
48. Pareja F, Lee JY, Brown DN *et al*. The genomic landscape of mucinous breast cancer. *J. Natl. Cancer Inst.* 2019; **111**; 737–741.
49. Nguyen B, Veys I, Leduc S *et al*. Genomic, transcriptomic, epigenetic, and immune profiling of mucinous breast cancer. *J. Natl. Cancer Inst.* 2019; **111**; 742–746.
50. Tognon C, Knezevich SR, Huntsman D *et al*. Expression of the ETV6-NTRK3 gene fusion as a primary event in human secretory breast carcinoma. *Cancer Cell* 2002; **2**; 367–376.
51. Li D, Xiao X, Yang W *et al*. Secretory breast carcinoma: a clinicopathological and immunophenotypic study of 15 cases with a review of the literature. *Mod. Pathol.* 2012; **25**; 567–575.
52. Roux P, Knight S, Cohen M *et al*. Tubular and mucinous breast cancer: results of a cohort of 917 patients. *Tumori* 2019; **105**; 55–62.
53. Chen R, Wang Y, Li T *et al*. Oncotype DX 21-gene test has a low recurrence score in both pure and mixed mucinous breast carcinoma. *Oncol. Lett.* 2021; **22**; 771.
54. Turashvili G, Brogi E, Morrow M *et al*. The 21-gene recurrence score in special histologic subtypes of breast cancer with favorable prognosis. *Breast Cancer Res. Treat.* 2017; **165**; 65–76.
55. Skotnicki P, Sas-Korczynska B, Strzepek L *et al*. Pure and mixed mucinous carcinoma of the breast: a comparison of clinical outcomes and treatment results. *Breast J.* 2016; **22**; 529–534.
56. Liu F, Yang M, Li Z *et al*. Invasive micropapillary mucinous carcinoma of the breast is associated with poor prognosis. *Breast Cancer Res. Treat.* 2015; **151**; 443–451.
57. Ranade A, Batra R, Sandhu G, Chitale RA, Balderacchi J. Clinicopathological evaluation of 100 cases of mucinous carcinoma of breast with emphasis on axillary staging and special reference to a micropapillary pattern. *J. Clin. Pathol.* 2010; **63**; 1043–1047.
58. Barbashina V, Corben AD, Akram M, Vallejo C, Tan LK. Mucinous micropapillary carcinoma of the breast: an aggressive counterpart to conventional pure mucinous tumors. *Hum. Pathol.* 2013; **44**; 1577–1585.
59. Pan B, Yao R, Shi J *et al*. Prognosis of subtypes of the mucinous breast carcinoma in Chinese women: a population-based study of 32-year experience (1983-2014). *Oncotarget* 2016; **7**; 38864–38875.
60. Wei YN, Liu S, Zhang ML, Ke XX, Chen M, Wei B. Clinicopathologic characteristics of HER2-positive pure mucinous breast carcinoma: a systematic investigation into an unusual tumor. *Int. J. Clin. Exp. Pathol.* 2019; **12**; 1666–1677.
61. Jang Y, Jung H, Kim HN *et al*. Clinicopathologic characteristics of HER2-positive pure mucinous carcinoma of the breast. *J. Pathol. Transl. Med.* 2020; **54**; 95–102.
62. Jin J, Li B, Cao J *et al*. Analysis of clinical features, genomic landscapes and survival outcomes in HER2-low breast cancer. *J. Transl. Med.* 2023; **21**; 360.
63. Sun P, Zhong Z, Lu Q *et al*. Mucinous carcinoma with micropapillary features is morphologically, clinically and genetically distinct from pure mucinous carcinoma of breast. *Mod. Pathol.* 2020; **33**; 1945–1960.
64. Shet T, Chinoy R. Presence of a micropapillary pattern in mucinous carcinomas of the breast and its impact on the clinical behavior. *Breast J.* 2008; **14**; 412–420.
65. Xu X, Bi R, Shui R *et al*. Micropapillary pattern in pure mucinous carcinoma of the breast - does it matter or not? *Histopathology* 2019; **74**; 248–255.
66. Brogi E, Wen HY, Desmedt C, Reis-Filho JS, Schmitt F. Mucinous cystadenocarcinoma. In: *WHO Classification of Tumours Editorial Board. Breast tumours. WHO Classification of Tumours*. 5th ed. Vol **2**. Lyon: IARC, 2019.
67. Koenig C, Tavassoli FA. Mucinous cystadenocarcinoma of the breast. *Am. J. Surg. Pathol.* 1998; **22**; 698–703.
68. Wang X, Li Y, Zhao P *et al*. Primary mucinous cystadenocarcinoma of the breast: a clinicopathologic analysis of one case and review of the literature. *Int. J. Clin. Exp. Pathol.* 2020; **13**; 2562–2568.
69. Honma N, Sakamoto G, Ikenaga M, Kuroiwa K, Younes M, Takubo K. Mucinous cystadenocarcinoma of the breast: a case report and review of the literature. *Arch. Pathol. Lab Med.* 2003; **127**; 1031–1033.
70. Nayak A, Bleiweiss IJ, Dumoff K, Bhuiya TA. Mucinous cystadenocarcinoma of the breast: report of 2 cases including one with long-term local recurrence. *Int. J. Surg. Pathol.* 2018; **26**; 749–757.
71. Chen WY, Hu YH, Tsai YH *et al*. Mucinous cystadenocarcinoma of the breast harbours TRPS1 expressions and PIK3CA alterations. *Histopathology* 2024; **84**; 550–555.
72. Zheng Y, Tang H, Liu Q *et al*. Mutational analysis and protein expression of PI3K/AKT pathway in four mucinous cystadenocarcinoma of the breast. *Diagn. Pathol.* 2025; **20**; 68.
73. Guo S, Wang Y, Rohr J *et al*. Solid papillary carcinoma of the breast: a special entity needs to be distinguished from conventional invasive carcinoma avoiding over-treatment. *Breast* 2016; **26**; 67–72.
74. Brogi E, MacGrogan G, Collins LC, Rakha EA, Tan BY, Lerwill M. Solid papillary carcinoma (in situ and invasive). In: *WHO*

© 2026 John Wiley & Sons Ltd., *Histopathology*

13652559, 0, Downloaded from https://onlinelibrary.wiley.com/doi/10.1111/his.70088 by George Mason University, Wiley Online Library on [10/03/2026]. See the Terms and Conditions (https://onlinelibrary.wiley.com/terms-and-conditions) on Wiley Online Library for rules of use; OA articles are governed by the applicable Creative Commons License

Classification of Tumours Editorial Board. Breast tumours. WHO Classification of Tumours. 5th ed. Vol **2**. Lyon: IARC, 2019.
75. Nassar H, Qureshi H, Adsay NV, Visscher D. Clinicopathologic analysis of solid papillary carcinoma of the breast and associated invasive carcinomas. *Am. J. Surg. Pathol.* 2006; **30**; 501–507.
76. Moritani S, Ichihara S, Kushima R *et al*. Myoepithelial cells in solid variant of intraductal papillary carcinoma of the breast: a potential diagnostic pitfall and a proposal of an immunohistochemical panel in the differential diagnosis with intraductal papilloma with usual ductal hyperplasia. *Virchows Arch.* 2007; **450**; 539–547.
77. Tan PH, Schnitt SJ, van de Vijver MJ, Ellis IO, Lakhani SR. Papillary and neuroendocrine breast lesions: the WHO stance. *Histopathology* 2015; **66**; 761–770.
78. Piscuoglio S, Ng CK, Martelotto LG *et al*. Integrative genomic and transcriptomic characterization of papillary carcinomas of the breast. *Mol. Oncol.* 2014; **8**; 1588–1602.
79. Rosa M, Mohammadi A, Masood S. Lobular carcinoma of the breast with extracellular mucin: new variant of mucin-producing carcinomas? *Pathol. Int.* 2009; **59**; 405–409.
80. Cserni G, Floris G, Koufopoulos N *et al*. Invasive lobular carcinoma with extracellular mucin production-a novel pattern of lobular carcinomas of the breast. Clinico-pathological description of eight cases. *Virchows Arch.* 2017; **471**; 3–12.
81. Singh K, DiazGomez B, Wang Y, Ou J, Hansen K. Invasive lobular carcinoma with extracellular mucin: not all mucinous mammary carcinomas are ductal! *Int. J. Surg. Pathol.* 2019; **27**; 55–58.
82. Baig A, Omeroglu-Altinel G, Omeroglu A. Invasive pleomorphic-type lobular carcinoma of the breast presenting as a mucinous carcinoma. *Case Rep. Pathol.* 2019; **2019**; 1839208.
83. Burky MJ, Ray EM, Ollila DW, O'Connor SM, Hertel JD, Calhoun BC. Pleomorphic invasive lobular carcinoma of the breast with extracellular mucin and *HER2* amplification. *Breast Cancer (Auckl.)* 2020; **14**; 1178223420976383.
84. Yu J, Bhargava R, Dabbs DJ. Invasive lobular carcinoma with extracellular mucin production and HER-2 overexpression: a case report and further case studies. *Diagn. Pathol.* 2010; **5**; 36.
85. Soong TR, Dillon DA, Rice-Stitt TL *et al*. Invasive lobular carcinoma with extracellular mucin (ILCEM): clinicopathologic and molecular characterization of a rare entity. *Mod. Pathol.* 2022; **35**; 1370–1382.
86. Pesoli C, Youssef M, Wei S. Salivary gland-type carcinomas of the breast: a review and update with emphasis on molecular advances and differential diagnosis. *Arch. Pathol. Lab Med.* 2022; **146**; 1319–1328.
87. Di Tommaso L, Foschini MP, Ragazzini T *et al*. Mucoepidermoid carcinoma of the breast. *Virchows Arch.* 2004; **444**; 13–19.
88. Camelo-Piragua SI, Habib C, Kanumuri P, Lago CE, Mason HS, Otis CN. Mucoepidermoid carcinoma of the breast shares cytogenetic abnormality with mucoepidermoid carcinoma of the salivary gland: a case report with molecular analysis and review of the literature. *Hum. Pathol.* 2009; **40**; 887–892.
89. Sanati S, Leonard M, Khamapirad T, Eltorky MA. Nodular mucinous of the breast: a case report with pathologic, ultrasonographic, and clinical findings and review of literature. *Arch. Pathol. Lab Med.* 2005; **129**; e58–e61.
90. Carney JA. Carney complex: the complex of myxomas, spotty pigmentation, endocrine overactivity, and schwannomas. *Semin. Dermatol.* 1995; **14**; 90–98.
91. Balci P, Kabakci N, Topcu I, Canda T, Güray M, Özfidan S. Breast myxoma: radiologic and histopathologic features. *Breast J.* 2007; **13**; 88–90.
92. Bennett AK, Mills SE, Wick MR. Salivary-type neoplasms of the breast and lung. *Semin. Diagn. Pathol.* 2003; **20**; 279–304.
93. Reid-Nicholson M, Bleiweiss I, Pace B, Azueta V, Jaffer S. Pleomorphic adenoma of the breast. A case report and distinction from mucinous carcinoma. *Arch. Pathol. Lab Med.* 2003; **127**; 474–477.
94. Wargotz ES, Norris HJ. Metaplastic carcinomas of the breast. I. Matrix-producing carcinoma. *Hum. Pathol.* 1989; **20**; 628–635.

© 2026 John Wiley & Sons Ltd., *Histopathology*

13652559, 0, Downloaded from https://onlinelibrary.wiley.com/doi/10.1111/his.70088 by George Mason University, Wiley Online Library on [10/03/2026]. See the Terms and Conditions (https://onlinelibrary.wiley.com/terms-and-conditions) on Wiley Online Library for rules of use; OA articles are governed by the applicable Creative Commons License